

Central Scotoma with no Apparent Abnormalities on Fundoscopy - Case Report of Placoid Neuroretinitis Mimicking Retrobulbar Neuritis

Pedro Três Vieira Gomes^{1*}, Paulo Tadeu Silva Campos¹, Julia Pontes Sousa¹, Davi Três Vieira Gomes², Isabela Rita de Carvalho Cunha³, Natanael de Abreu Sousa³, Leticia Rosa Ribeiro Cunha⁴ and Kamilla Siqueira de Oliveira¹

¹Ophthalmology Resident in Hospital Oftalmológico de Brasília, Brasília, DF, Brazil

²Medical Student in Escola de Ciências Médicas da Santa Casa de Vitória, Vitória, ES, Brazil

³Strabismus, Neurophthalmology and Ophthalmopediatry Preceptor in Hospital Oftalmológico de Brasília, Brasília, DF, Brazil

⁴Strabismus and Ophthalmopediatry Department, Hospital Oftalmológico de Brasília, Brazil

***Corresponding Author:** Pedro Três Vieira Gomes, Ophthalmology Resident in Hospital Oftalmológico de Brasília, Brasília, DF, Brazil.

Received: December 07, 2021

Abstract

Patients presenting with low visual acuity (BAV) of acute installation, associated or not with field defects, without apparent fundoscopic changes, are labeled as possible carriers of retrobulbar optic neuritis. However, before starting a neurological investigation, some data from anamnesis and clinical examination are essential for the differential diagnosis with subclinical retinopathies (occult maculopathy).

This clinical report presents the case of a patient complaining of sequential bilateral central scotoma, with no apparent alteration in the background biomicroscopy, in which, due to some subtle clinical characteristics, it was possible to get rid of the diagnostic trap, which pointed to demyelinating retrobulbar neuritis.

Through the multimodal analysis of the retina, associated with other complementary exams, it was possible to identify that it was an infectious placoid neuroretinitis caused by syphilis.

The case presented here demonstrates the importance of delving into the signs and symptoms associated with low painless visual acuity or the presentation of central scotomas, in a patient with apparently normal fundoscopy. In the absence of a relative afferent defect and in the presence of positive visual symptoms (photopsia), it should be borne in mind that the most likely location remains the retina, ruling out the possibility of retrobulbar neuritis.

Keywords: Scotoma; Visual Acuity; Posterior Uveitis; Acute Posterior Multifocal Placental Pigment Epitheliopathy; Neurosyphilis

Introduction

Patients presenting with low visual acuity (BAV) of acute installation, associated or not with field defects, without apparent fundoscopic changes, are labeled as possible carriers of retrobulbar optic neuritis. However, before starting a neurological investigation, some data from anamnesis and clinical examination are essential for the differential diagnosis with subclinical retinopathies (occult maculopathy) [1,2].

Thus, the presence of positive scotomas or photopsia in a patient with reduced visual acuity, without a relative afferent defect, associated or not with vascular or inflammatory changes (uveitis), suggests that the pathology has its origin in the macula and not in the optic

Central Scotoma with no Apparent Abnormalities on Fundoscopy - Case Report of Placoid Neuroretinitis Mimicking Retrobulbar Neuritis

nerve [3]. The use of complementary exams to study the retina, especially those of multimodal imaging (optical coherence tomography, autofluorescence, angiofluoresceinography and retinography) can help guide the diagnosis in difficult cases [4], when the patient “cannot see” and the ophthalmologist nor does he find any apparent ocular alteration that justifies it.

Following is the clinical report of a patient complaining of sequential bilateral central scotoma, with no apparent alteration in the background biomicroscopy, in which, due to some subtle clinical characteristics, it was possible to get rid of the diagnostic trap, which pointed to demyelinating retrobulbar neuritis.

Case Report

SDS, male, 56 years old, presented with a complaint of fixed, semi-opaque, dark spot in the central visual field, associated with slight turbidity, in the left eye (LE), with subacute evolution of 3 days. Upon palpebral occlusion of both eyes, he noticed sporadic photopsia. History of myalgia (upper limbs) and arthralgia of large migratory joints (wrist and shoulders) in the last 5 months. Weight loss of 7 kg in the last 4 months, unaccompanied by fever.

On ophthalmological examination, he had corrected visual acuity of 20/20 in the right eye (DO) and 20/25 in OE. DO fundoscopy showed a pink optic disc, 0.2x0.3 excavation, slight blurring of the margins, but without hyperemia, without telangiectasia, and without vitreous reaction and OE with a pink optic disc, sharp edges, 0.2x0.3 excavation; in both eyes, macula and vessels without changes. Preserved direct and consensual pupil reflexes preserved, without relative afferent defect.

One week after the first consultation, there was spontaneous resolution of the central scotoma of the left eye, but the patient returned with the same complaint, this time, in the contralateral (right) eye. On ophthalmological examination, he presented visual acuity of 20/80 (OD) and 20/20 (OE).

The multimodal evaluation of the retina showed, on retinography (Figure 1) macular pigmentary changes in both eyes, and blurring of the optical disc with capillary dilation in the nasal sector, only in the right eye; on angiofluoresceinography (Figure 2) hyperfluorescence in the right optic papilla; and on optical coherence tomography (OCT) (Figure 2) discontinuity of the ellipsoid zone (ZE), thickening and irregularity of the retinal pigment epithelium (RPE) in macular areas corresponding to the pigmentary changes presented in the retinography of both eyes [5]; Humphrey 24 - 2 computerized campimetry (first two images) and Humphrey 10 - 2 visual campimetry (two lower images) (Figure 3) showed relative central scotoma in both eyes.

The clinical picture, in conjunction with the complementary exams, pointed to bilateral placoid neuroretinitis, leaving the etiological diagnosis to be made, above all, discarding an infectious agent [6-8].

In this context, the patient was referred to hospital. His neurological examination did not show focal deficits. Magnetic resonance imaging of the skull and orbit were without significant changes. Laboratory tests showed increased ESR (27mm in the first hour), reagent FAN (1/80), positive serum VDRL (1/512), positive serum FTA-ABs and reagent VDRL in CSF.

Neurotherapy was initiated (24 million IU per day of intravenous crystallized aqueous penicillin G, divided into doses of 4 million IU 4/4 hours, for 14 days) [9,10].

The patient returned for consultation four months after hospital discharge, asymptomatic, with visual acuity of 20/20 in both eyes. Retinography (Figure 1) showed the disappearance of pigmentary changes in the macular region of both eyes; the optical coherence tomography (Figure 2) showed recovery of the reflectivity of the ellipsoid zone and RPE in both eyes; Humphrey 24-2 computerized campimetry (Figure 3 and 4) of both eyes, showed improvement in macular retinal sensitivity and reduction in the extent of relative scotomas;

Central Scotoma with no Apparent Abnormalities on Funduscopy - Case Report of Placoid Neuroretinitis Mimicking Retrobulbar Neuritis

Papilla OCT (Figure 2) showed atrophy of the nerve fiber layer of the peridiscal retina and lower nasal neural rhyme in the right eye and lower in the left eye, sequelae to the inflammatory condition.

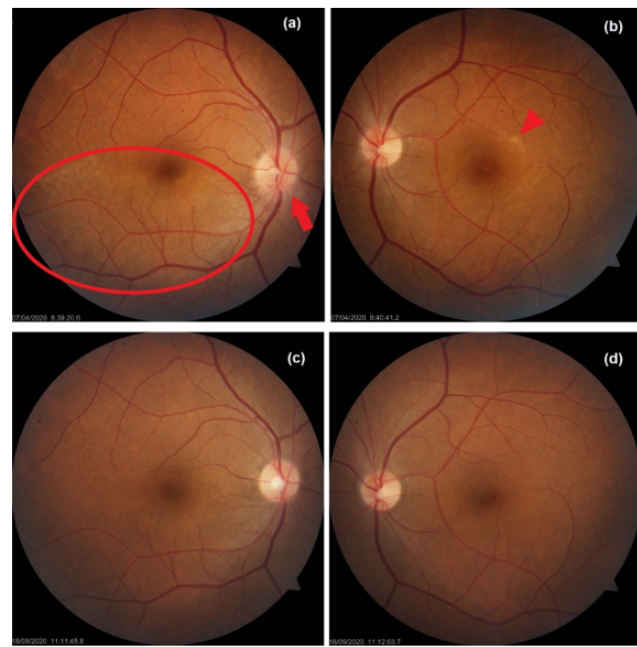


Figure 1: Blurry and hyperemia of the right optic disc [red arrow] and hypopigmentation area, mottled yellow-brown, inferior to the fovea [red circle] (a); yellowish pigmented area in the upper temporal macular region [red arrowhead] (b); 4 months after treatment ended, regression of papilla edema (c) and macular pigmentary changes in both eyes.

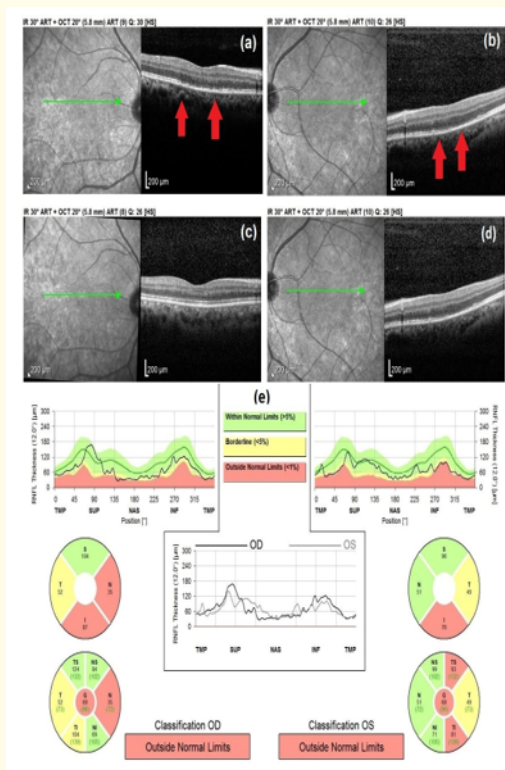


Figure 2: Angiofluoresceinography: hyperfluorescence in the right optic papilla (a); no changes in OE (b); OCT both eyes: discontinuity of the ellipsoid zone and thickening and irregularity of the retinal pigment epithelium [red arrows] (c) and (d); normalization of reflectivity of all layers of the sensorineural retina and RPE (e) and (f) and atrophy of the nerve fiber layer of the peridiscal retina, sequelae to the inflammatory condition (g).

Central Scotoma with no Apparent Abnormalities on Fundscopy - Case Report of Placoid Neuroretinitis Mimicking Retrobulbar Neuritis

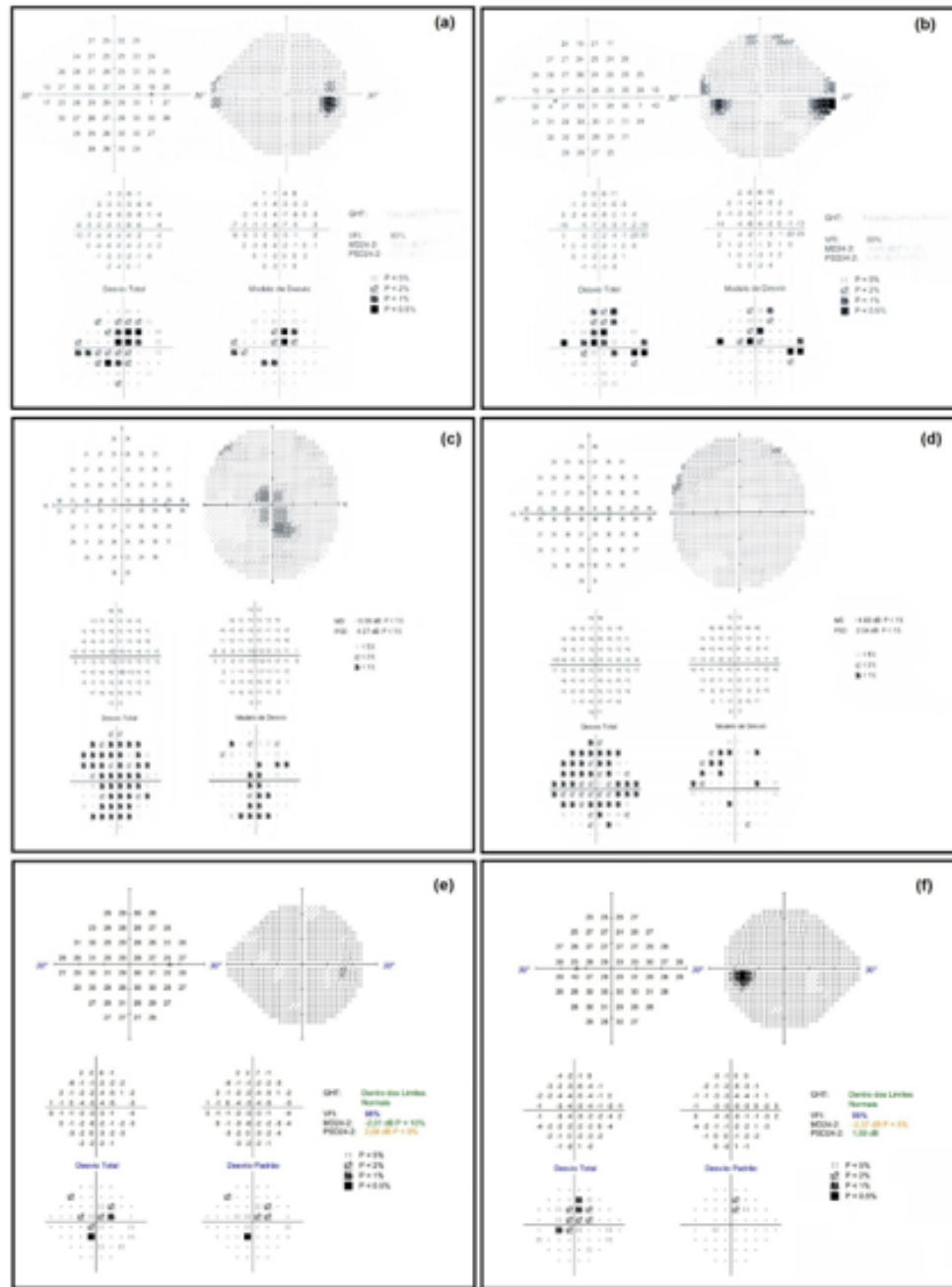


Figure 3: Humphrey 24-2 (a, b) and 10-2 (c, d) computed field scan of both eyes: central relative scotoma; campimetry 4 months after treatment (e, f): improvement of macular retinal sensitivity and reduction in the extent of relative scotomas.

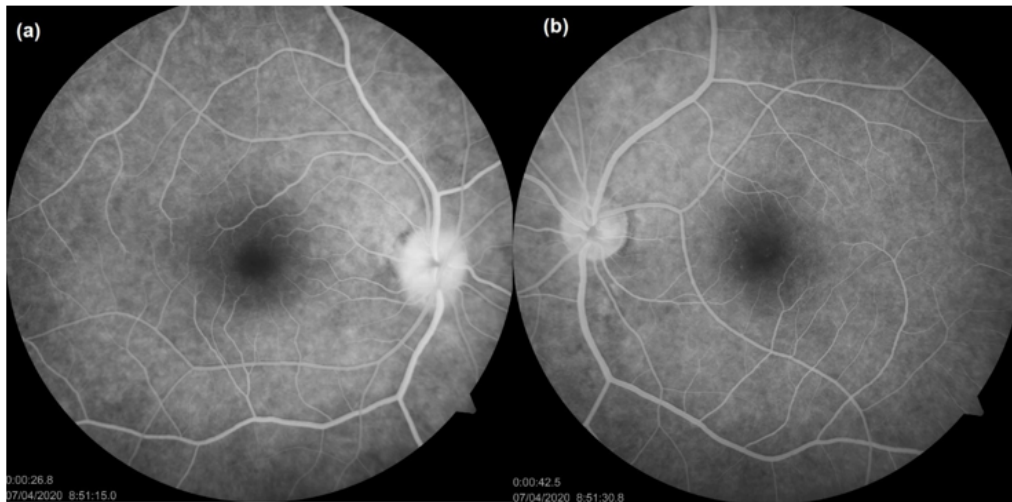


Figure 4

Discussion

The case presented here demonstrates the importance of delving into the signs and symptoms associated with low painless visual acuity or the presentation of central scotomas, in a patient with apparently normal fundoscopy. In the absence of a relative afferent defect and in the presence of positive visual symptoms (photopsia), it should be kept in mind that the most likely location remains the retina², ruling out the possibility of retrobulbar neuritis. In these cases, the multimodal retinal evaluation is extremely important to guide the syndromic and etiological diagnosis⁸. Patients like the one in this case report may need a multidisciplinary medical evaluation: ophthalmology, neurology and infectology.

Funding Support

Self-funding.

Approved by the Following Research Ethics Committee

Hospital Oftalmológico de Brasília, Brasília, DF. N^o CAAE: 40607420.7.0000.5667

Disclosure of Potential Conflicts of Interest

The authors declare no potential conflict of interest.

Clinical Trial Number on a Public Registry

No.

Bibliography

1. Demachki NT, *et al.* "Occult macular dystrophy". *Revista Brasileira de Oftalmologia* 79.2 (2020): 128-130.
2. Alves MR. "Retina e Vítreo. 4ª Edição Conselho Brasileiro de Oftalmologia. Retina e Vítreo / Conselho Brasileiro de Oftalmologia: coordenador Milton Ruiz Alves; editores Marcos Ávila, Jacó Lavinsky, Carlos Augusto Moreira Junior. - 4. edition. - Rio de Janeiro: Cultura Médica (2016).
3. Alves MR. "Uveítes. 4ª Edição Conselho Brasileiro de Oftalmologia. Uveítes / Conselho Brasileiro de Oftalmologia: coordenador Milton Ruiz Alves; editores Fernando Oréfice, Clovis Arcoverde Freitas Neto, Vinícius Monteiro de Castro et al. - 4. edition. - Rio de Janeiro: Cultura Médica (2016).
4. Meira-Freitas Daniel, *et al.* "Achados da tomografia de coerência óptica e angiografia com indocianina verde na coroidopatia placóide posterior aguda sífilítica: relato de caso". *The Arquivos Brasileiros de Oftalmologia* 72.6 (2009): 832-835.
5. Ramalho A. "Retina - Volume I. 1ª edição - Dezembro de. Thêa Portugal SA (2013): 199-202.
6. Britto P, *et al.* "Caracterização Multimodal das Alterações Corrioretinianas Verificadas na Coriorretinite Posterior Placóide Sífilítica Aguda. Revista da Sociedade Portuguesa de Oftalmologia". Janeiro-Março 2013 *Oftalmologia* 37.1 (2013): 45-50.
7. Avelleira JCR and Bottino G. "Sífilis: diagnóstico, tratamento e controle". *An. Bras. Dermatol.* Rio de Janeiro 81.2 (2006).
8. Gass JD, *et al.* "Acute syphilitic posterior placoid chorioretinitis". *Ophthalmology* 97.10 (1990): 1288-1297.
9. Barros AM, *et al.* "Neurossífilis. ISSN 0871-3413 • ©Arqui Med (2005).
10. Caixeta L, *et al.* "Neurossífilis: Uma Breve Revisão". *Revista de Patologia Tropical* 43.2 (2014): 121-129.

Volume 13 Issue 2 February 2022

©All rights reserved by Pedro Três Vieira Gomes, *et al.*